



## Review

# Bronchoscopy During Non-Invasive Mechanical Ventilation: A Review of Techniques and Procedures<sup>☆</sup>

Antonio Esquinas,<sup>a</sup> Marcos Zuñil,<sup>b</sup> Raffaele Scala,<sup>c</sup> Eusebi Chiner<sup>d,\*</sup>

<sup>a</sup> Unidad de Cuidados Intensivos, Hospital Morales Meseguer, Murcia, Spain

<sup>b</sup> Unidad de Neumología, Hospital Ernest Lluch, Calatayud, Zaragoza, Spain

<sup>c</sup> Unità Operativa di Pneumologia e Unità di Terapia Intensiva Polmonare, Ospedale S. Donato, Arezzo, Italy

<sup>d</sup> Servicio de Neumología, Hospital Universitario San Juan, Alicante, Spain

## ARTICLE INFO

### Article history:

Received 10 May 2012

Accepted 22 May 2012

Available online 15 February 2013

### Keywords:

Non-invasive mechanical ventilation

Bronchoscopy

Bronchoscopy under non-invasive ventilation

Intubation

### Palabras clave:

Ventilación mecánica no invasiva

Fibrobroncoscopia

Fibrobroncoscopia bajo ventilación no invasiva

Intubación guiada por broncoscopio

## ABSTRACT

Non-invasive mechanical ventilation (NIMV) is used to treat acute respiratory failure by improving gas exchange abnormalities and reducing the signs of respiratory effort, dyspnea and the activity of accessory respiratory muscles. Bronchoscopy is a key technique in the study of respiratory diseases that is necessary to perform in acute and critical patients, most of the times only after orotracheal intubation (OTI) due to possible complications of the technique. In this review, we evaluate the evidence of NIMV use during bronchoscopy, concluding that its use should be considered in severe patients as an alternative that is capable of preventing the complications related with OTI and mechanical ventilation, especially in patients with chronic obstructive pulmonary disease and with a tendency toward developing hypercapnia.

© 2012 SEPAR. Published by Elsevier España, S.L. All rights reserved.

## Broncoscopia durante la ventilación mecánica no invasiva: revisión de técnicas y procedimientos

## RESUMEN

La ventilación mecánica no invasiva (VMNI) actúa en el tratamiento de la insuficiencia respiratoria aguda mejorando las alteraciones del intercambio gaseoso y reduciendo los signos de trabajo respiratorio, la disnea y la actividad de la musculatura respiratoria accesoria. La broncoscopia es una técnica clave en el estudio de las enfermedades respiratorias que es necesario practicar, en ocasiones en pacientes agudos o críticos; la única opción es ser realizada tras intubación orotraqueal (IOT), debido a las posibles complicaciones de la técnica. En la presente revisión evaluamos la evidencia del uso de la VMNI en el transcurso de la broncoscopia, concluyendo que su utilización debiera considerarse, en pacientes graves, como alternativa capaz de evitar complicaciones relacionadas con la IOT y la ventilación mecánica invasiva (VMI), especialmente en pacientes con enfermedad pulmonar obstructiva crónica y con tendencia a la hipercapnia.

© 2012 SEPAR. Publicado por Elsevier España, S.L. Todos los derechos reservados.

## Introduction

Non-invasive mechanical ventilation (NIMV) applied in the treatment of acute respiratory failure improves gas exchange alterations and reduces the signs of respiratory effort, dyspnea and the

activity of the accessory respiratory musculature while any drugs that are administered take effect.<sup>1</sup> In this manner, patients may be more quickly stabilized and tracheal intubation (TI), invasive mechanical ventilation (IMV) and admittance to an intensive care unit (ICU) can all be avoided.<sup>2</sup>

Bronchoscopy is a fundamental technique used in the study of respiratory diseases. It provides visualization of the upper airway and initial divisions of the tracheobronchial tree and allows for samples to be taken from the trachea, bronchi, mediastinum and lung parenchyma.<sup>3</sup> Furthermore, it is essential in the therapeutic management of patients with hemoptysis, aspiration of a foreign body, excess secretions, neoplastic lesions and obstruction of the

<sup>☆</sup> Please cite this article as: Esquinas A, et al. Broncoscopia durante la ventilación mecánica no invasiva: revisión de técnicas y procedimientos. Arch Bronconeumol. 2013;49:105–12.

\* Corresponding author.

E-mail address: [chiner\\_eus@gva.es](mailto:chiner_eus@gva.es) (E. Chiner).

central airway. Bronchoscopy has become a key element in modern pulmonology: it has diagnostic indications in most respiratory diseases and is the cornerstone in some aspects of current respiratory therapy methods.<sup>4</sup> Among the different types of bronchoscopy, flexible bronchoscopy (introduced in 1968 by Ikeda et al.<sup>5</sup>) is the most widely used technique, although there are other types, such as rigid bronchoscopy (RB)<sup>6</sup> or ultrasound-guided bronchoscopy (EBUS).<sup>7,8</sup>

### Non-Invasive Mechanical Ventilation and Bronchoscopy

When considering bronchoscopy in patients under NIMV, acute cases (critical patients with the need for emergency or preferential interventions) should be differentiated from those with long-term or home NIMV who would require non-emergency or scheduled bronchoscopy.<sup>9</sup>

The first group includes patients who require preferential treatment, such as secretion suctioning, bronchoscopy-guided intubation<sup>10</sup>—especially in patients with swallowing alterations and risk for lung aspiration (myopathies with bulbar involvement)—or the extraction of foreign bodies.

The presence of abundant secretions in patients with acute respiratory failure is one of the causes for NIMV failure, which can contraindicate its use.<sup>11</sup> However, bronchoscopy can facilitate the elimination of secretions, improve ventilation and avoid tracheal intubation. This therapeutic bronchoscopy has even been adapted to the NIMV in patients with pathologies such as cystic fibrosis with severe exacerbations and abundant secretions.<sup>12</sup> It may also be used in patients with pulmonary infiltrates of unknown origin who may require microbiological samples to be taken, or those of another nature (diffuse alveolar hemorrhage or organizing pneumonia<sup>13</sup>). Other indications for bronchoscopy in patients with NIMV include the study of atelectasis, hemoptysis, torpidly evolving pneumonia in immunosuppressed patients, suspicion of lung neoplasia, bronchopleural fistulas or tracheoesophageal fistulas.

Performing bronchoscopy presents potential complications that can be related with the procedure itself, individual patient factors or with the ability, qualifications and experience of the bronchoscopist.

The gas exchange alterations that occur during bronchoscopy can be triggered by the object of the bronchoscopic study, but the bronchoscope itself also causes dysfunctions as it takes up around 10% of the tracheal lumen—diminishing its caliber—, increases the resistance of the airway and reduces tidal volume. The impact of bronchoscopy on increased flow resistance will depend on the caliber of the respiratory tract and/or the size of the bronchoscope. The increased respiratory effort associated with increased resistive loading can precipitate acute respiratory failure in critical patients. In addition, the application of suction through the bronchoscope channel lowers airway pressure at the end of expiration, facilitating early alveolar closure. This may cause arterial oxygen pressure (PaO<sub>2</sub>) to decrease between 10 and 20 mmHg during bronchoscopy.<sup>14</sup> These changes persist after the procedure is completed, and the time that the gas exchange takes to normalize ranges from 15 min in normal subjects and several hours in patients with lung disease. All this justifies the use of supplemental O<sub>2</sub> in patients at risk for desaturation during bronchoscopy.<sup>15</sup>

Moreover, the bronchoscope itself has an irritating effect on the mucosa as it passes through the respiratory tract, which frequently generates cough, nausea, vomiting and laryngeal, tracheal or bronchial spasms. These reflexes, largely dependent on the cranial nerve pairs IX, X and XI, produce discomfort and neurovegetative overstimulation. This is counteracted with the administration of topical anesthesia, such as lidocaine, or with

intravenous anesthetics, such as propofol, used in cases of allergy to the former.<sup>16,17</sup> The administration of these topical anesthesia, saline solution or techniques like bronchoalveolar lavage (BAL) can worsen hypoxemia as a consequence of an altered ventilation–perfusion ratio.<sup>18</sup> This can become aggravated when greater sedation is required with anesthesia due to the intolerance to the procedure.

In patients with chronic obstructive pulmonary disease (COPD) and other obstructive disease, bronchoscopy can promote air trapping as functional residual capacity increases up to 17% and auto-PEEP increases. These effects can be deleterious in patients with hypercapnic respiratory failure or in those who initiate with decompensation from their baseline disease.<sup>19</sup>

It should be mentioned that bronchoscopy is occasionally indicated in critical or high-risk patients in order to reach an etiologic diagnosis, either opting for TI to perform bronchoscopy or assuming empirical treatment in cases of infectious lung disease, aimed at avoiding the exploration. Taking into account that associations like the American Thoracic Society consider bronchoscopy a contraindication for BAL when a PaO<sub>2</sub> of 75 mmHg or an FiO<sub>2</sub> of 90% are not reached during spontaneous ventilation with O<sub>2</sub> supply, TI is usually opted for when bronchoscopy is essential.<sup>20</sup> However, IMV entails a series of risks related with the insertion of the endotracheal tube, associated respiratory infections, intrinsic IMV problems or those observed after the withdrawal of the endotracheal tube. NIMV is an alternative that is able to avoid complications related with intubation and mechanical ventilation, especially in patients with COPD and a tendency toward hypercapnia.<sup>21</sup> Spontaneous ventilation maintained during the procedure guarantees the balance of the V/Q ratio and hemodynamic stability, allowing for bronchoscopy to be done.<sup>22</sup>

It is well known that NIMV can maintain airway permeability, ease drainage of secretions and improve respiratory effort. It has been demonstrated that the simple administration of continuous positive airway pressure (CPAP) can improve minute volume and reduce the probability of atelectasis. This fact is more notable in patients with tracheomalacia.<sup>23</sup> CPAP, which acts as a sort of “pneumatic stent” mechanism, can increase transmural pressure of the central airways, increasing its cross-sectional diameter. Nevertheless, this is not the only mechanism that can explain the improvement in ventilatory variables. Elevating lung volume increases peak expiratory flow, residual functional capacity and the effectiveness of cough, which is especially important in patients with neuromuscular disease or weakened respiratory musculature.<sup>24</sup>

Although CPAP is not strictly considered a NIMV system due to absence of inspiratory support, lower risk has been observed for acute respiratory failure after bronchoscopy in cases where this system has been used.<sup>25,26</sup> Other similar studies showed improvement in the PaO<sub>2</sub>/FiO<sub>2</sub> ratio at the expense of elevated PaO<sub>2</sub> compared with patients treated with conventional oxygen therapy.<sup>27</sup> The beneficial effect of NIMV in bronchoscopy has also been confirmed in patients with COPD effected by pneumonia and hypercapnic encephalopathy.<sup>28,29</sup> In addition, it has been demonstrated that in moderate–severe hypercapnic encephalopathy of exacerbated COPD patients, short-term survival is similar when using NIMV or IMV, although there are fewer complications in the former.<sup>21</sup>

### Procedure

#### Setting

It is usually recommended that the procedure be performed in an ICU or intermediate respiratory care setting, or a standard bronchoscopy room capable of dealing with any complications.<sup>19</sup>

### Application of Non-Invasive Mechanical Ventilation

NIMV should be initiated in a previously non-ventilated patient at least 15 or 20 min before bronchoscopy is begun.<sup>14,27</sup>

There are no published papers comparing the different NIMV methods. Initially, double-pressure systems were used with support mode (IPAP 17 cm and EPAP 5 cm) and  $\text{FiO}_2$  at 100%,<sup>30</sup> but procedures have been described with lower inspiratory pressures and  $\text{FiO}_2$  at 70%.<sup>31</sup> A support pressure of 10 cm during the procedure is recommended.<sup>28</sup> It has also been proposed to carry out bronchoscopy in a specific CPAP mode, specifically Boussignac CPAP, coupled to a face mask.<sup>26</sup> This system is based on the so-called law of conservation of energy in motion, by which gas enters at high speed coming from a flow meter and passes through microcapillaries. This generates acceleration in the form of microjets that cause the air molecules of the jet to transfer part of the kinetic energy to the air molecules situated in the CPAP body, which are thus accelerated (virtual valve or turbulence effect). The gas velocity transforms into pressure depending on the flow of gas provided by the flow meter.<sup>32</sup>

It is recommended to begin with IPAP at 14–15 cm and EPAP at 5 cm with bi-pressure systems (or 10 cm of support pressure) and 5 cm when CPAP is used, except if different parameters were previously established due to the characteristics of the patient.<sup>27,28</sup>  $\text{FiO}_2$  is usually used at a level that would provide  $\text{O}_2$  saturation above 90%. On a practical level, this implies an  $\text{FiO}_2$  greater than 0.5 or a flow between 6 and 12 l/min. Preferentially,  $\text{FiO}_2$  is usually started at 1 and then reduced according to patient tolerance.<sup>33</sup> Obviously, in order to reach the desired pressure with the Boussignac CPAP model, the required level marked by the flow meter is used.

Generally, other parameters would include the S/T mode (spontaneous/timed), a rate of 4–8 mandatory inspirations and an I/E ratio (inspiration/expiration) according to the characteristics of the patient (usually 1:2, 1:3 in patients with airflow obstruction and 1:1 in restrictive patients). With respirators that allow for it to be monitored, expiratory tidal volume ( $V_t$ ) should be at between 8 and 10 ml/kg and respiratory rate always below  $25 \text{ min}^{-1}$ . Monitoring the pressure curve and flow can help assess patient–respirator interaction, although data are still needed to demonstrate its usefulness in the NIMV/bronchoscopy scenario.

#### CPAP Masks

Regarding CPAP interfaces, almost all types of masks have been used. The most widely used are face masks,<sup>30,31</sup> which provide for oral or nasal entry of the bronchoscope.

Currently, endoscopic face masks usually have two orifices: one for the administration of gas and a second orifice that is sealed and distensible and allows for an endoscope to be introduced (Figs. 1 and 2).

Some authors have proposed modifications in the interfaces based on the presence of a second orifice with a silicone diaphragm for the entry of the bronchoscope.<sup>34</sup> There are also universal T connections for coupling with any type of mask (Fig. 3). When Boussignac CPAP is used for bronchoscopy, face masks are used.<sup>26</sup> Antonelli described the possibility of performing bronchoscopy with NIMV using a helmet-type interface, which completely covers the patient's head to maintain ventilatory support<sup>35</sup> (Fig. 4).

Heunks et al.<sup>36</sup> has designed a system based on a complete face mask with the insertion of a synthetic plastic cylinder in the mask in order to avoid air leaks during bronchoscopy. Twelve hypoxemic patients ( $\text{PaO}_2/\text{FiO}_2$ :  $192 \pm 23$ ) underwent bronchoscopy with BAL without any important complications (Fig. 5). A similar system is shown in Fig. 6.

Chiner et al.<sup>37</sup> have recently published the results of a prospective study with 35 patients that used a hand-made system of a

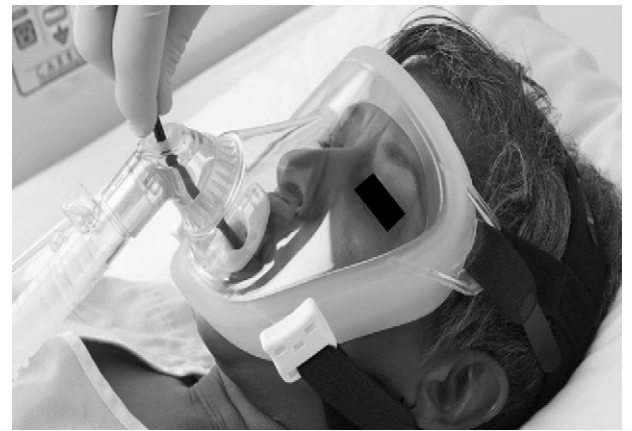

Fig. 1. Face mask for non-invasive mechanical ventilation with diaphragm for the entry of the bronchoscope; oral insertion through the mouthpiece.

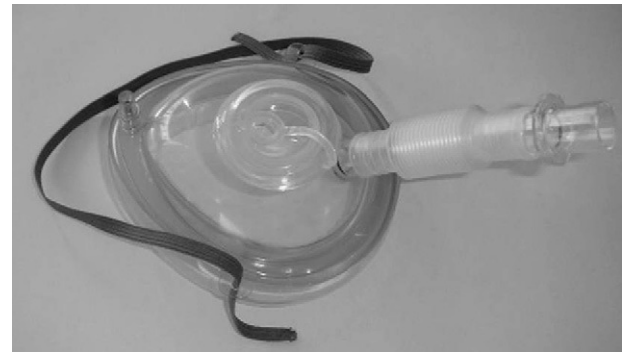

Fig. 2. Variation of an oronasal mask equipped with an insertion diaphragm, independent from the non-invasive mechanical ventilation supply channel.

membrane made out of a latex glove coupled with a bite block with a small incision. This maintains the pressure administered by BIPAP through a nasal mask, and bronchoscopy is carried out orally with good diagnostic and therapeutic results (Fig. 7).

#### Sedation

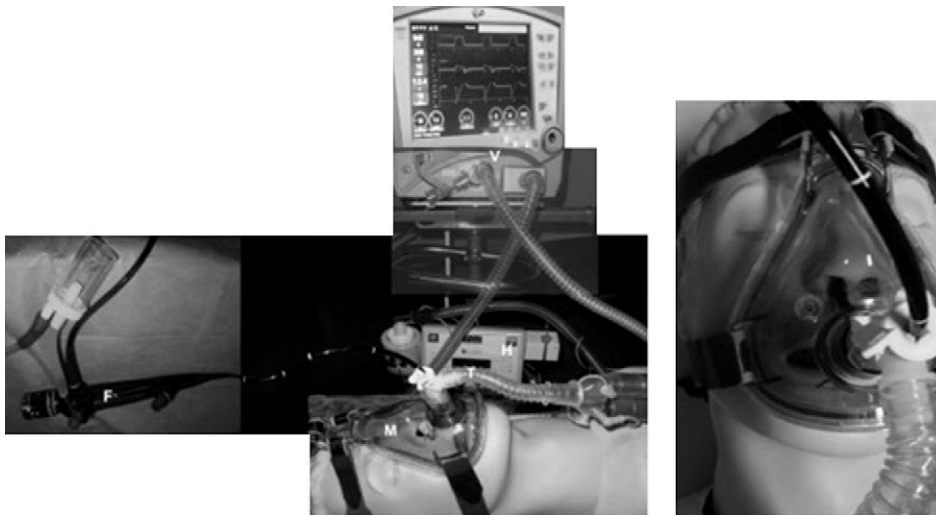
NIMV does not necessarily imply greater sedation. In fact, it is not unadvised, although it is essential to have the necessary experience in drug management. For topical anesthesia, lidocaine is usually used, following standard bronchoscopy procedure. Some authors propose the use of propofol for bronchoscopies done under NIMV, which reduces patient discomfort without significant adverse effects.<sup>38</sup>

#### Patient Position

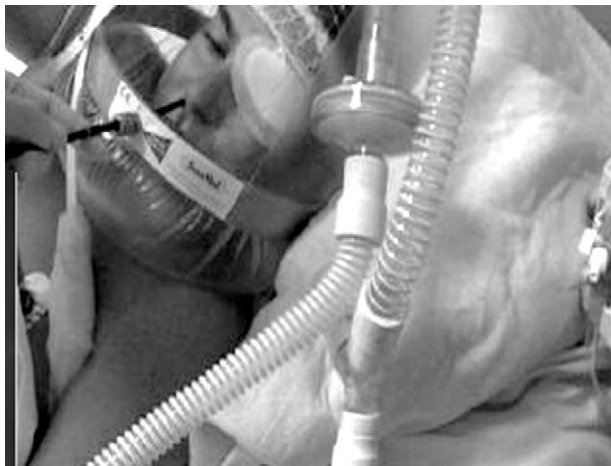It is recommended to carry out the procedure with the patient in a semi-recumbent position, which is implied by the anterior entry of the bronchoscope. However, NIMV itself has been used in supine decubitus in order to optimize respiratory parameters in other explorations like transesophageal ultrasound or interventional cardiology (or in cases with diagnosis of dynamic airway collapse, which required maintaining the patient in this position).<sup>39–41</sup>

#### Nasal vs Oral Insertion

There are authors who have used both nasal and oral approaches. In many instances, this is determined by the mask used. With the case of face masks, nasal or oral pathways can be used.<sup>27,28</sup>



**Fig. 3.** Oronasal mask with a coupled T-piece that allows for the bronchoscope to be inserted through the nose.



**Fig. 4.** Helmet-type interface for non-invasive mechanical ventilation; by insertion of the bronchoscope through a fenestrated piece, either the nasal or oral approach can be used.

Oral insertion can also be used with modifications and systems coupled to a bite block, with the concomitant use of a nasal mask.<sup>42</sup> In explorations with the helmet, either nasal or oral entry could be used, with the patient sitting or in supine decubitus.<sup>35</sup> Likewise, the use of Boussignac CPAP, since it is an open system, allows for

oral or nasal entry.<sup>26</sup> The unintentional loss of pressure (interface) during bronchoscopy should be controlled in order to be able to guarantee NIMV effectiveness.

#### Techniques

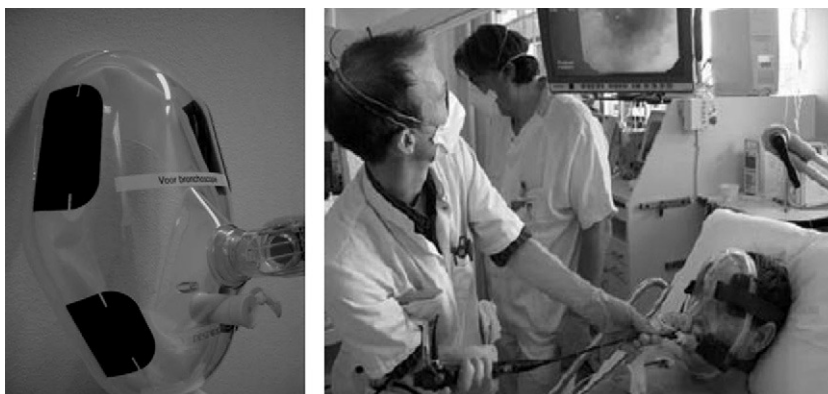The techniques used are conditioned by patient characteristics. Bronchial suction, BAL or protected catheter are usually used for microbiological or cytological diagnosis.<sup>28,37</sup> Although it is not formally contraindicated, some authors recommend not performing transbronchial biopsy while the patient is under mechanical ventilation due to greater risk for pneumothorax and bleeding.<sup>14,43-45</sup>

#### Duration

As in all interventions in high-risk patients, it is recommended to take the shortest time possible in order to achieve the objective. It usually varies, but the mean duration of bronchoscopy with NIMV in patients with pneumonia is approximately 8 min.<sup>28</sup>

#### Post-Bronchoscopy Care

NIMV will be maintained with parameters similar to those prior to bronchoscopy within 15 and 90 min after the end of the procedure.<sup>12,23,29,41</sup>



**Fig. 5.** Face mask for non-invasive mechanical ventilation, coupled to a fenestrated cylindrical piece for the insertion of the bronchoscope.

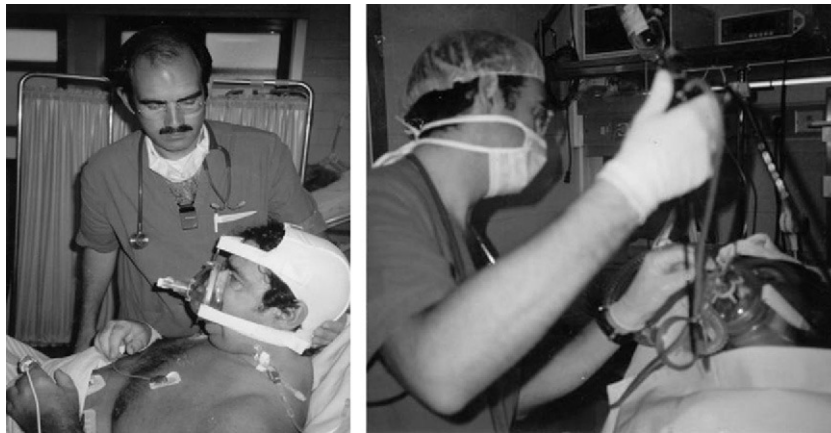

Fig. 6. Variation of Fig. 5, with an oronasal mask.

### Complications

Since NIMV offers inspiratory flow at positive pressures, patients may present with gastric distension and increased risk for bronchoaspiration. The abdominal pressure generated by intragastric distension can reduce functional residual capacity and add a restrictive component.<sup>46</sup> NIMV requires a high degree of patient collaboration, which facilitates coupling to the respirator, reducing the probability of gastric distension and restrictive-type alveolar collapse.

There are also other complications related with bronchoscopy (desaturation, bleeding, poor collaboration, agitation,

etc.), whose resolution is approached as in a standard bronchoscopy procedure.

Less frequently, there may be major cardiovascular complications (malignant arrhythmias, acute coronary syndrome, cardiac arrest), which can be minimized through proper patient selection and monitoring during bronchoscopy.

Immediate NIMV adjustments (hypoxemia, hypercapnia, maladjustment, discomfort) during the test are done according to standard practice, summarized below:

If there is hypoxemia, EPAP is increased  $2 \times 2$  cmH<sub>2</sub>O until an O<sub>2</sub> saturation  $\geq 90\%$  is reached. It should be kept in mind that very high values (greater than 10) can cause greater risk for gastric

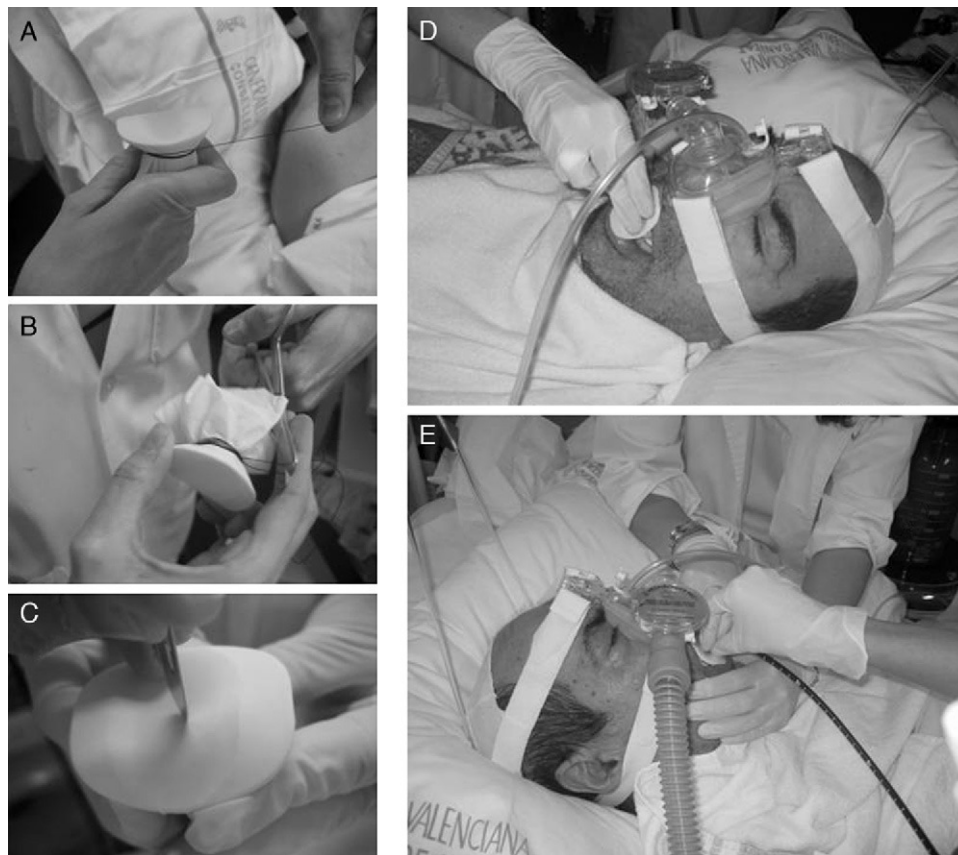

Fig. 7. Non-invasive mechanical ventilation carried out with a nasal mask and insertion of the bronchoscope through the mouth. (A) Bite block placed inside a latex glove and held with a suture. (B) Excess material is cut off. (C) Minimal incision in the membrane of the mouthpiece. (D) Introduction of the bite block under non-invasive mechanical ventilation. (E) Oral insertion of bronchoscope and technique carried out with non-invasive ventilation.

distension and intolerance in the patient. If it persists, the flow or  $\text{FiO}_2$  is increased.

Hypercapnia is corrected by raising IPAP to the point that good pH margins are reached (maximum 25  $\text{cmH}_2\text{O}$ ) and by adjusting EPAP to avoid rebreathing.

Patient maladjustment is observed with certain signs or data: contraction of the sternocleidomastoid (which will condition IPAP), abdominal contraction or active expiration (which would recommend reducing IPAP), failed inspiration (which would justify the increase in EPAP) and low  $V_t$  (requiring the mask to be adjusted, avoiding a peak pressure higher than 30  $\text{cmH}_2\text{O}$  and permitting leaks if the expired volume were adequate).<sup>47</sup>

Nasal or facial injuries secondary to the use of the mask are not included in this section as they appear after prolonged NIMV use (a minimum of several hours).

Persistent patient desaturation or clinical deterioration would require the procedure to be suspended and additional measures to be taken, including TI.

Therefore, it is important to emphasize that the procedure should be evaluated in an adequate setting by experts in bronchoscopy with fast access to TI if cardiopulmonary resuscitation were needed.<sup>48</sup>

### Contraindications

Contraindications of this procedure are those of NIMV itself, such as cardiac arrest, severe encephalopathy, severe gastrointestinal bleeding, severe hemodynamic instability, a history of facial surgery or trauma, inability to guarantee a permeable airway or high risk for aspiration.<sup>22</sup> Some related contraindications are psychomotor agitation, respiratory failure due to neurological causes or asthma state.<sup>33</sup> Contraindications due to facial deformities or facial, esophageal or gastric interventions<sup>36</sup> should also not be overlooked. Others, such as airway obstruction or the inability to cough up secretions, can become indications for bronchoscopy with NIMV.<sup>28</sup> There are other absolute contraindications of bronchoscopy itself, such as the lack of collaboration, unstable angina, recent acute myocardial infarction (within the previous 20 days), severe arrhythmias, thrombopenia less than 60 000 or prothrombin activity below 60% if biopsy is planned.<sup>49</sup> Bronchial asthma is a relative contraindication with an  $\text{FEV}_1$  less than 60%.

The inability to maintain oxygen saturation above 85% despite maintaining high  $\text{FiO}_2$  is indicative of TI if bronchoscopy is being considered.<sup>50</sup> Patient cooperation is essential, but if this is not possible, TI or empirical treatment should be chosen.<sup>33</sup>

### Special Situations

#### *Orotracheal Intubation With Bronchoscopy and Non-Invasive Mechanical Ventilation*

Intubation with bronchoscopy is usually done as an emergency procedure in the ICU or as a scheduled procedure in the anesthesia department in cases of difficult intubation.

This can be dangerous due to the risk for secondary hypoxia after the apnea induced by general anesthesia. NIMV has been used for bronchoscopy in hypoxemic or hypercapnic patients and its use could be considered for tracheal intubation with bronchoscopy, including predictably difficult intubations, as long as the technique is strictly followed.<sup>51</sup>

The masks used are face masks with 2 orifices, as previously commented. These masks provide an  $\text{FiO}_2$  of 1 and ensure the gaseous mix with no leaks. In addition, with ventilation with positive pressure, distension of the pharyngeal–tracheal structures is obtained during inspiration and visualization of the glottis is

improved during bronchoscopy. By adding positive end-expiratory pressure (PEEP), the glottis is maintained open during expiration.<sup>52</sup>

Many intubations are nasotracheal, and in these cases the technique entails applying local anesthesia to the nostrils and oropharynx, placement of the endoscopic mask over the face, connection to the respirator and, finally, entry of the bronchoscope through the previously lubricated orotracheal tube until reaching 3 cm from the carina. At this time, some authors administer midazolam if the saturation with NIMV surpasses 94%.<sup>53</sup> Other authors prefer administering midazolam once the tip of the endotracheal tube is visualized when it surpasses the distal end of the bronchoscope passes. During the progression of the endotracheal tube using the bronchoscope as a guide, the scope will be set so it does not come out of the trachea due to the inertia of the endotracheal tube progressing along the bronchoscope. If resistance is felt while sliding the endotracheal tube, it could be useful to slightly withdraw the tube and then reinsert it while slightly rotating clockwise.<sup>54</sup> Once the tube is inside the trachea, the balloon is inflated, the bronchoscope is withdrawn, the mask is disconnected and the endotracheal tube is connected to the respirator.

TI with bronchoscopy through an endoscopic face mask, but with manual ventilation, is a technique described by certain groups. It is a technique that is used when intubation with laryngoscope has not been possible, but with no history of previous use of NIMV.<sup>55</sup>

Occasionally, bronchoscopy can be done after TI or nasotracheal intubation with a thin endotracheal tube, introducing the bronchoscope parallel to and outside of the endotracheal tube without inflating the sleeve. This provides for simultaneous ventilation of the patient, as long as the leak amount is tolerable. It can be used for quick procedures that involve transitory IMV (maintaining the endotracheal tube) or NIMV (reverting sedation and extubation) after completion. As we have commented, these procedures should be done by experienced teams and in the ICU or similar settings.<sup>19,48</sup>

### Pediatric Patients

Pediatric patients are at a high risk for hypoxemia and hypercapnia during bronchoscopy due to the smaller diameter and the greater tendency for collapse of their airways. In addition, there is increased resistance in the airways created by the bronchoscope itself.<sup>56</sup> Any obstruction due to edema, lesion occupying space or elements that reduce the cross-sectional diameter for the bronchoscope will exponentially increase the resistance to gas flow (ley de Hagen–Poiseuille), limiting ventilation by significant reductions in tidal volume, peak inspiratory pressure and expiratory flow.<sup>57</sup>

CPAP increases the width of the laryngeal space and reduces the tendency toward collapse of the lateral walls of the pharynx, which are the most sensitive structures of the upper airway.<sup>58</sup> Bronchoscopy in pediatric patients with spontaneous breathing has been associated with a decrease in tidal volume and respiratory flow, which can be reverted with the use of CPAP. In pediatric patients with tracheomalacia, where pulmonary volumes are low and resistance to expiratory flow is high, NIMV improves lung volumes and expiratory flow.<sup>59</sup>

#### *Sleep Apnea Hypopnea Syndrome/Obesity Hypoventilation Syndrome/Morbid Obesity*

In these patients, the hypoxemia triggered during bronchoscopy, increased on occasion by the effect of sedation, can be truly important, to the point that, even without it, hypercapnia while awake may worsen.<sup>60</sup> NIMV counteracts negative inspiratory pressures and the hypotonicity of the upper airway muscles of these patients, applying positive pressure on the oropharynx.<sup>33</sup> In addition, in this type of patients it has been described that, under conditions of moderate sedation, the collapse of some areas

like the hypopharynx can limit the visualization of the structures through the bronchoscope.<sup>61</sup> The positive pressure generated by NIMV allows for the laryngeal structures to be identified as the device passes the hypopharynx and is introduced through the vocal chords. This aspect is fundamental in these cases, which are usually considered as having difficult intubation.<sup>62</sup>

#### *Rigid Bronchoscopy and Non-Invasive Mechanical Ventilation*

Major applications for rigid bronchoscopy include therapeutic bronchoscopy (laser, electrocautery or cryotherapy), the placement of tracheobronchial stents, tumor resection, dilation of tracheobronchial stenosis and the extraction of foreign bodies, particularly in children. Other indications are the treatment of hemoptysis and taking deep biopsies, obtained with the rigid biopsy forceps and completed with other techniques like bronchial cryotherapy.<sup>6,63</sup>

The application of intermittent positive pressure and jet ventilation are the 2 standard ventilatory modes that guarantee effective ventilation during RB.<sup>64</sup> Patients can also be controlled with assisted spontaneous breathing, but this may cause low levels of respiratory acidosis.

Some authors have proposed the use of negative-pressure ventilation (NPV), a NIMV mode, as a system of optimal ventilation for RB procedures. With the aim to assess the effectiveness of NPV using a poncho wrap system during the application of laser therapy in endobronchial lesions, Vitacca developed a randomized, controlled, prospective study that confirmed its usefulness in patients with apnea. During the laser therapy procedure under general anesthesia, this system avoided the development of hypercapnia, secondary respiratory acidosis and the increased need for O<sub>2</sub> supply.<sup>65</sup> In a later paper, the use of NPV in patients undergoing rigid bronchoscopy demonstrated a reduced use of opioids, shorter recovery time, less respiratory acidosis and less need for assisted manual ventilation and O<sub>2</sub>.<sup>66</sup>

#### *Endobronchial Ultrasound*

Endobronchial ultrasound (EBUS) is a minimally invasive diagnostic technique that complements flexible bronchoscopy. It is a cutting-edge tool that combines traditional video-assisted endoscopy and ultrasound, which can obtain ultrasound images of the structures outside the bronchial walls, such as lymph nodes.<sup>67</sup> There are 2 different EBUS techniques, depending on the type of transducer: radial EBUS and linear EBUS.

The technique is done under sedation by the bronchoscopist or anesthetist. After placing an oropharyngeal cannula in the mouth, the ultrasound bronchoscope is inserted. To date, there are no prospective studies published about the advantage of using NIMV in ultrasound bronchoscopy, although its future use is likely, probably with the application of high-frequency NIMV modalities.

#### **Conclusions and Practical Recommendations<sup>27,28,48,68,69</sup>**

NIMV is a safe therapeutic procedure that allows for complementary tests like bronchoscopy to be carried out, with ventilatory support that provides efficacy similar to IMV. However, it must be supervised by expert staff, and on occasion it requires an ICU or intermediate respiratory care unit setting with proper monitoring, NIMV management and preparation if TI or IMV were necessary.

Once it has been decided to do bronchoscopy with NIMV, NIMV treatment should be initiated previously and its efficacy in the patient verified. Patient cooperation is essential (except in children or scheduled intubations).

Bronchoscopy should be done by an experienced bronchoscopist, guaranteeing a precise, quick test. In cases where improvement in the gas exchange is not observed after previous

treatment with NIMV or inability to maintain oxygen saturation above 85% despite maintaining high FiO<sub>2</sub>, TI should be scheduled without delay and should be done under the best possible conditions.

#### **Conflict of Interests**

The authors declare having no conflict of interests.

#### **References**

- Nava S, Navalesi P, Conti G. Time of non-invasive ventilation. *Intensive Care Med.* 2006;32:361–70.
- Esquinas Rodríguez AM, Ayuso Baptista F, Minaya García JA, Artacho Ruiz R, Salguero Piedras M, Suero Méndez C, et al. Ventilación mecánica en urgencias, emergencias y transporte sanitario. Metodología. In: Esquinas Rodríguez A, editor. *Tratado de ventilación mecánica no invasiva.* Madrid: Grupo Aula Médica; 2006. p. 509–17.
- Weiss YG, Deutschman CS. The role of fiberoptic bronchoscopy in airway management of the critically ill patient. *Crit Care Clin.* 2000;16:445–51.
- Villegas Fernández FR, Callol Sánchez LM, Carrillo Aranda B. Broncoscopia. In: Carlos V, editor. *Enfermedades respiratorias. 2.ª ed.* Madrid: Grupo Aula Médica; 2009. p. 75–86.
- Ikeda S, Yanai N, Ishikawa S. Flexible bronchoscope. *Keio J Med.* 1968;17:1.
- Wain JC. Rigid bronchoscopy: the value of a venerable procedure. *Chest Surg Clin N Am.* 2001;11:691–9.
- Yasufuku K, Nakajima T, Chiyo M, Sekine Y, Shibuya K, Fujisawa T. Endobronchial ultrasonography: current status and future directions. *J Thorac Oncol.* 2007;2:970–9.
- Colt HG, Davoudi M, Murgu S. Scientific evidence and principles for the use of endobronchial ultrasound and transbronchial needle aspiration. *Expert Rev Med Devices.* 2011;8:493–513.
- Ambrosino N, Guarracino F. Unusual applications of non-invasive ventilation. *Eur Respir J.* 2011;38:440–9.
- Dellinger RP, Bandi V. Fiberoptic bronchoscopy in the intensive care unit. *Crit Care Clin.* 1992;8:755–72.
- British Thoracic Society Standards of Care Committee. Non-invasive ventilation in acute respiratory failure. *Thorax.* 2002;57:192–211.
- Disdier C. Broncoscopia con soporte ventilatorio mecánico no invasivo. In: Esquinas Rodríguez AM, editor. *Tratado de ventilación mecánica no invasiva. Práctica clínica y metodológica.* Madrid: Grupo Aula Médica; 2006. p. 429–31.
- Confalonieri M, Potena A, Carbone G, Porta RD, Tolley EA, Umberto Meduri G. Acute respiratory failure in patients with severe community-acquired pneumonia. A prospective randomized evaluation of non-invasive ventilation. *Am J Respir Crit Care Med.* 1999;160:1585–91.
- Herrejón A, Simó M, Pérez ME, Chiner E, Marín J. Comparación de la presión arterial y transcutánea de oxígeno durante la fibrobroncoscopia. *Arch Bronconeumol.* 1989;25:80–3.
- Golpe R, Mateos A. Supplemental oxygen during flexible bronchoscopy. *Chest.* 2002;121:663–4.
- Reed A. Preparation of the patient for awake flexible fiberoptic bronchoscopy. *Chest.* 1992;101:813–6.
- Bose AA, Colt HG. Lidocaine in bronchoscopy. Practical use and allergic reactions. *J Bronchol.* 2008;15:163–6.
- Credle Jr WF, Smiddy JF, Shea DW, Elliott RC. Fiberoptic bronchoscopy in acute respiratory failure in the adult. *N Engl J Med.* 1973;288:49–50.
- Ambrosino N, Vaghegini G. Noninvasive positive pressure ventilation in the acute care setting: where are we? *Eur Respir J.* 2008;31:874–86.
- Goldstein RA, Rohatgi PK, Bergofsky EH, Block ER, Daniele RP, Dantzker DR, et al., American Thoracic Society. Clinical role of bronchoalveolar lavage in adults with pulmonary disease. *Am Rev Respir Dis.* 1990;142:481–6.
- Scala R, Nava S, Conti G, Antonelli M, Naldi M, Archinucci I, et al. Non-invasive versus conventional ventilation to treat hypercapnic encephalopathy in COPD. *Intensive Care Med.* 2007;33:2101–8.
- Nava S, Hill N. Non-invasive ventilation in acute respiratory failure. *Lancet.* 2009;374:250–9.
- Wiseman NE, Duncan PG, Cameron CB. Management of tracheo-bronchomalacia with continuous positive airway pressure. *J Pediatr Surg.* 1985;20:489–93.
- Rozycki HJ, Van Houten ML, Elliott GR. Quantitative assessment of intrathoracic airway collapse in infants and children with trachea-bronchomalacia. *Pediatr Pulmonol.* 1996;21:241–5.
- International Consensus Conference in Intensive Care Medicine: non-invasive positive pressure ventilation in acute respiratory failure. *Am J Respir Crit Care Med.* 2001;163:283–91.
- Maitre B, Jaber S, Maggiore SM, Bergot E, Richard JC, Bakthiari H, et al. Continuous positive airway pressure during fiberoptic bronchoscopy in hypoxemic patients. A randomized double-blind study using a new device. *Am J Respir Crit Care Med.* 2000;162:1063–7.
- Antonelli M, Conti G, Rocco M, Arcangeli A, Cavaliere F, Proietti R, et al. Noninvasive positive-pressure ventilation vs conventional oxygen supplementation in hypoxemic patients undergoing diagnostic bronchoscopy. *Chest.* 2002;121:1149–54.

28. Scala R, Naldi M, Maccari U. Early fiberoptic bronchoscopy during noninvasive ventilation in patients with decompensated chronic obstructive pulmonary disease due to community acquired pneumonia. *Crit Care*. 2010;14:R80.
29. Jain P. Bronchoscopy for bone marrow transplant patients. *J Bronchol*. 2006;13:49-51.
30. Antonelli M, Conti G, Riccioni L, Meduri GU. Noninvasive positive-pressure ventilation via face mask during bronchoscopy with BAL in high risk hypoxemic patients. *Chest*. 1996;110:724-8.
31. Da Conceição M, Genco G, Favier JC, Bidallier I, Pitti R. Fiberoptic bronchoscopy during noninvasive positive-pressure ventilation in patients with chronic obstructive lung disease with hypoxemia and hiperapnea. *Ann Fr Anesth Reanim*. 2000;19:231-6.
32. Boussignac G, Esquinas Rodríguez AM, González Díaz G. Utilización actual de la CPAP Boussignac®-Vygón en la ventilación mecánica no invasiva. In: Esquinas Rodríguez AM, editor. *Tratado de Ventilación Mecánica No Invasiva*. Madrid: Aula Médica; 2006. p. 187-9.
33. Murgu SD, Pecson J, Colt HG. Bronchoscopy during non-invasive ventilation: indications and technique. *Respir Care*. 2010;55:595-600.
34. Da Conceição M, Genco G, Włodarczyk S, Favier JC, Pitti R. Ventilation manuelle avec un masque facial modifié pendant l'intubation sous fibroscopie. *Ann Fr Anesth Reanim*. 1999;18:607-8.
35. Antonelli M, Pennisi MA, Conti G, Bello G, Maggiore SM, Michetti V, et al. Fiberoptic bronchoscopy during noninvasive positive pressure ventilation delivered by helmet. *Intensive Care Med*. 2003;29:126-9.
36. Heunks LM, de Bruin CJ, van der Hoeven JG, van der Heijden HF. Noninvasive mechanical ventilation for diagnostic bronchoscopy using a new face mask: an observational feasibility study. *Intensive Care Med*. 2010;36:143-7.
37. Chiner E, Sancho-Chust JN, Llombart M, Senent C, Camarasa A, Signes-Costa J. Fiberoptic bronchoscopy during nasal non-invasive ventilation in acute respiratory failure. *Respiration*. 2010;80:321-6.
38. Chiner E, Bui HN, Guilhon E, Grenouillet-Delacré M, Leger MS, Saghi T, et al. Fiberoptic bronchoscopy under noninvasive ventilation and propofol target-controlled infusion in hypoxemic patients. *Intensive Care Med*. 2011;37:1969-75.
39. Guarracino F, Cabrini L, Baldassarri R, Cariello C, Covelto RD, Landoni G. Non-invasive ventilation-aided transoesophageal echocardiography in high-risk patients: a pilot study. *Eur J Echocardiogr*. 2010;11:554-6.
40. Guarracino F, Cabrini L, Baldassarri R, Petronio S, De Carlo M, Covelto RD, et al. Noninvasive ventilation for awake percutaneous aortic valve implantation in high-risk respiratory patients: a case series. *J Cardiothorac Vasc Anesth*. 2011;25:1109-12.
41. Adliff M, Ngato D, Keshavjee S, Brenaman S, Granton JT. Treatment of diffuse tracheomalacia secondary to relapsing polycondritis with continuous positive airway pressure. *Chest*. 1997;112:1701-4.
42. Chiner E, Llombart M, Signes-Costa J, Andreu AL, Gómez-Merino E, Pastor E, et al. Description of a new procedure for fiberoptic bronchoscopy during noninvasive ventilation through a nasal mask in patients with acute respiratory failure. *Arch Bronconeumol*. 2005;41:698-701.
43. Wahidi MM, Rocha AT, Hollingsworth JW, Govert JA, Feller-Kopman D, Ernst A. Contraindications and safety of transbronchial lung biopsy via flexible bronchoscopy: a survey of pulmonologists and review of the literature. *Respiration*. 2005;72:285-95.
44. Bulpa PA, Dive AM, Mertens L, Delos MA, Jamart J, Evrard PA, et al. Combined bronchoalveolar lavage and transbronchial lung biopsy: safety and yield in ventilated patients. *Eur Respir J*. 2003;21:489-94.
45. O'Brien JD, Ettinger NA, Shevlin D, Kollef MH. Safety and yield of transbronchial biopsy in mechanically ventilated patients. *Crit Care Med*. 1997;25:440-6.
46. Mehta S, Hill N. State of the art: noninvasive ventilation. *Am J Resp Crit Care Med*. 2001;163:540-77.
47. Expósito Albuquerque M, Garrido Cabañas ML, Garrido Romero JJ, González Vergara D, Porras Pérez EM, Casolivé Carbonell V. Procedimientos en VMNI de pacientes agudos o crónicos agudizados. In: Barrot Cortés E, Sánchez G, editors. *Ventilación Mecánica No Invasiva*. Manual SEPAR de procedimientos. Barcelona: Respira; 2008. p. 25-44.
48. Scala R, Naldi M. Bronchoscopy in respiratory intensive care. *Clin Ter*. 2009;160:395-401.
49. Aspa Marco J, Prieto Vicente J. La fibrobroncoscopia en la urgencia respiratoria y en pacientes críticos. In: Díaz Agüero Álvarez P, Flandes Aldeyturriaga J, editors. *Broncoscopia diagnóstica y terapéutica*. Monografías Neumomadrid. Madrid: Ergón; 2007. p. 85-97.
50. Esteban A, Frutos-Vivar F, Ferguson ND, Arabi Y, Apezteguía C, González M, et al. Noninvasive positive-pressure ventilation for respiratory failure after extubation. *N Engl Med*. 2004;350:2452-60.
51. Favier JC, Da Conceição M, Genco G, Bidallier I, Fassassi M, Steiner T, et al. Fiberoptic intubation in adult patients with predictive signs of difficult intubation using sevoflurane and an endoscopic mask. *Ann Fr Anesth Reanim*. 2003;22:96-102.
52. Da Conceição M, Patrigeon JC, Favier JC. Intubación con fibroscopio y ventilación no invasiva. In: Esquinas Rodríguez AM, editor. *Tratado de Ventilación Mecánica No Invasiva*. Madrid: Aula Médica; 2006. p. 432-6.
53. Da Conceição M, Favier JC, Bidallier I, Armanet L, Steiner T, Genco G, et al. Fiberoptic intubation with non-invasive ventilation with an endoscopic facial mask. *Ann Fr Anesth Reanim*. 2002;21:256-62.
54. Asai T, Shingu K. Difficulty in advancing a tracheal tube over a fiberoptic bronchoscope: incidence, causes and solutions. *Br J Anesthesia*. 2004;92:870-81.
55. Favier JC, Da Conceição M, Genco G, Bidallier I, Fassassi M, Steiner T, et al. Fiberoptic intubation in adult patients with predictive signs of difficult intubation: inhalational induction using sevoflurane and an endoscopic facial mask. *Ann Fr Anesth Reanim*. 2003;22:96-102.
56. Schnapf BM. Oxygen desaturation during fiberoptic bronchoscopy in pediatric patients. *Chest*. 1991;99:591-4.
57. Kuna ST, Bedi DG, Ryckman C. Effect of nasal airway positive pressure on upper airway size and configuration. *Am Rev Respir Dis*. 1988;138:969-75.
58. Trachsel D, Erb TO, Frei FJ, Hammer J, Swiss Paediatric Respiratory Research Group. Use of continuous positive airway pressure during flexible bronchoscopy in young children. *Eur Respir J*. 2005;26:773-7.
59. Panitch HB, Allen JL, Alpert BE, Schidlow DV. Effects of CPAP on lung mechanics in infants with acquired tacheobronchomalacia. *Am J Respir Crit Care Med*. 1994;150:1341-6.
60. Mokhlesi B, Tulaimat A. Recent advances in obesity hypoventilation syndrome. *Chest*. 2007;132:1322-36.
61. Borowiecki B, Pollak CP, Weitzman ED, Rakoff S, Imperato J. Fibro-optic study of pharyngeal airway during sleep in patients with hypersomnia obstructive sleep-apnea syndrome. *Laryngoscope*. 1978;88:1310-3.
62. Rothfleisch R, Davis LL, Kuebel DA, deBoisblanc BP. Facilitation of fiberoptic nasotracheal intubation in a morbidly obese patient by simultaneous use of nasal CPAP. *Chest*. 1994;106:287-8.
63. Zuil M, Villegas F, Jareño J, Martos-Peregrín J, Llobregat N, Gómez Terreros FJ, et al. Cryotherapy in the diagnosis of endobronchial mucormycosis. *J Bronchol*. 2001;8:107-9.
64. Cavaliere S, Venuta F, Foccoli P, Toninelli C, La Face B. Endoscopic treatment of malignant airway obstructions in 2008 patients. *Chest*. 1996;110:1536-42.
65. Vitacca M. Ventilación mecánica no invasiva a presión negativa durante la broncoscopia rígida. In: Esquinas Rodríguez AM, editor. *Tratado de Ventilación Mecánica No Invasiva*. Madrid: Aula Médica; 2006. p. 426-8.
66. Natalini G, Cavaliere S, Seramondi V, Foccoli P, Vitacca M, Ambrosino N, et al. Negative pressure ventilation vs external high frequency oscillation during rigid bronchoscopy. A controlled randomized trial. *Chest*. 2000;118:18-23.
67. Pérez J. Eco-broncoscopia lineal: instrumental y técnica. In: Rosell A, editor. *Eco-broncoscopia*. Barcelona: ICG Marge; 2009. p. 27-30.
68. Robert D, Argaud L. Clinical review: long term noninvasive ventilation. *Crit Care*. 2007;11:210.
69. Jaber S, Chanques C. Another step for noninvasive ventilation in chronic obstructive pulmonary disease patients. *Crit Care*. 2010;14:163-4.